



THE COLLEGE OF
OPTOMETRISTS

Stage Two

Overarching case scenario 3

AGE AND GENDER ETHNIC BACKGROUND Female Aged 48 Caucasian

OCCUPATION AND HOBBIES Policy director for charity. Learning Spanish language at night class and enjoys independent travel in Europe as much as she can afford.

PRESENTING SYMPTOMS AND HISTORY Has had several episodes of laser treatment to both eyes over past two years, and vision decreased dramatically. Uses computer with enlargement and speech synthesis software, and CCTV in office. Needs something for reading travel books, correspondence, class notes. Very disturbed that she cannot make out the train/airport information board for journeys to work and on holiday trips.

GENERAL HEALTH AND MEDICATION Diagnosed with diabetes 16 years ago --- now controlled by Insulin injection x4 = 36 units per day. Beta-blocker for HBP and Lipostat.

PRESENT Rx, CENTRATION AND ACUITIES. CR39 Essilor Physio 3 Varifocals 2 years old

R. +0.25DS/+0.75x100 6/60

L. +0.75DS/+1.00x 90 6/60 monoc cd R32 L32

Add +2.50 R N30 L N30

PD/NCD 64/60 at 33cms

VISION 6/60 and 3/60

PINHOLE VISION RE 6/60 LE 6/60

REFRACTION RE +0.75D8 /+0.50X120

LE. +0.50DS/+0.75X90 Add +4.00

VA Distance RE 6/60L 6/60

Near RE N18 L N18 at 20 cm

ACCOMMODATION not tested

BINOCULAR STATUS

CT with and without Rx Distance. No movement detected

Near 4 XOP slow recovery

MOTILITY appears full - smooth pursuit

CONVERGENCE 9cms

PUPIL REACTIONS Direct, Consensual and Near responses intact but slow

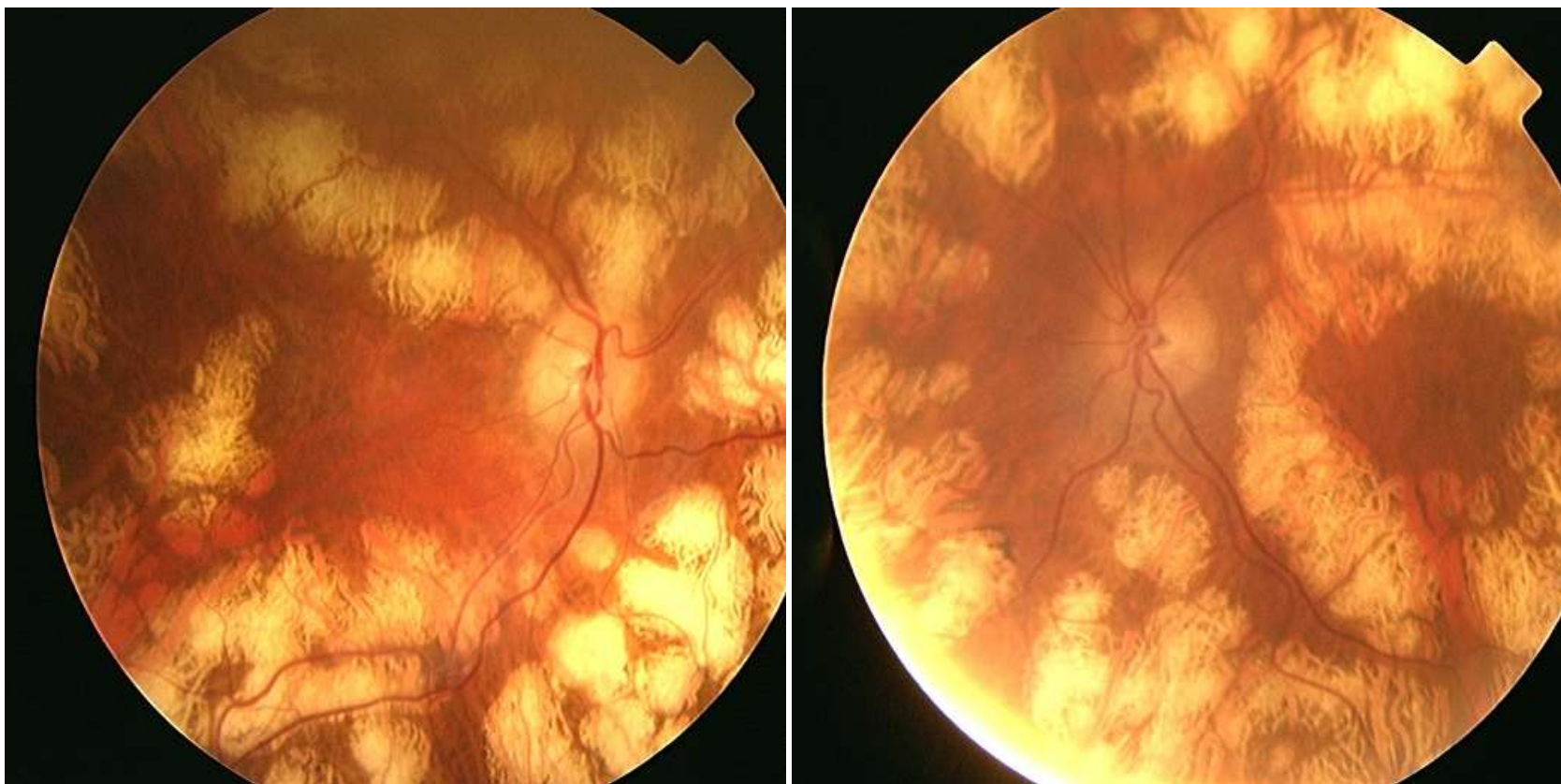
FUNDUS EXAMINATION see attached

FIELDS Not tested

IOP RE 21mmHg LE 21 mmHg 5.00pm Pulsair

EXTERNAL EYE EXAMINATION : see attached

Fundus Image



External Eyes

